


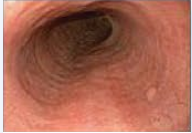




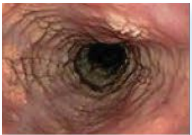






EoE Endoscopic Reference Score (EREFS)

The endoscopic reference score (EREFS) assesses 5 endoscopic findings: edema, rings, exudates, furrows, and strictures. EREFS total (0-20) is the sum of severity scores for proximal and distal regions of the esophagus, with higher scores indicating more severe endoscopic changes.¹⁻⁴

This modified scale is provided for informational purposes only. This is not a diagnostic tool.

Thresholds for clinically meaningful changes in the EoE EREFS have not been established.

Features	0	1	2	3
E Edema	 Absent Distinct vascularity present	 Loss of clarity or absence of vascular markings		
R Rings	 None	 Mild Subtle circumferential ridges	 Moderate Distinct rings, able to pass scope	 Severe Unable to pass scope
E Exudates	 None	 Mild Lesions involving <10% surface area	 Severe Lesions involving >10% surface area	
F Furrows	 Absent	 Present		
S Stricture	 Absent	 Present	Adapted from Hirano I, Moy N, Heckman MG, et al. <i>Gut</i> . 2013;62(4):489-495 and Vračarić V, Savić Ž, Živojinov M, et al. <i>Vojnosanit Pregl</i> . 2017;74(1):64-68. This is not a diagnostic tool and is provided for informational purposes only.	

References: 1. Hirano I, Moy N, Heckman MG, et al. *Gut*. 2013;62(4):489-495. 2. Lucendo AJ, Molina-Infante J, Arias A, et al. *United European Gastroenterol J*. 2017;5(3):335-358. 3. Collins MH, Dellon ES, Katzka DA, et al. *Am J Surg Pathol*. 2019;43(11):1501-1509. 4. Vračarić V, Savić Ž, Živojinov M, et al. *Vojnosanit Pregl*. 2017;74(1):64-68.

